



## Case report

# A case report of clinical outcome of a COVID-19 patient presented by acute ischemic stroke

**Md Reaz Uddin Chowdhury**<sup>\*1</sup>, **Sahedul Islam Bhuiyan**<sup>2</sup>, **Bimal Chandra Das**<sup>1</sup>, **Ashim Kumar Saha**<sup>1</sup>, **Sohel Rahman**<sup>3</sup>, **Md Nazmul Haq**<sup>4</sup>

1- Abdul Malek Ukil Medical College, Noakhali, Bangladesh.

2- Brahmanbaria Medical College, Brahmanbaria, Bangladesh.

3- Institute of Epidemiology Disease Control And Research, Dhaka, Bangladesh.

4- National Institute of Cardiovascular Diseases, Dhaka, Bangladesh.

### CASE REPORT INFO

#### Case Report history:

Received 18 October 2020

Received in revised form 24 November 2020

Accepted 2 December 2020

#### Keywords:

COVID-19

Severe pneumonia

Ischemic stroke

Thrombosis

### ABSTRACT

Corona virus disease 2019 (COVID-19) is a multisystem disease with many unusual presentations reported worldwide. Though it mostly involves the respiratory systems, it has also potential to invade neurological system. It can spread from respiratory systems to the central nervous system. Here we report a case of 70 years old female who was diagnosed as COVID-19 case by molecular diagnosis and admitted with the features of acute ischemic stroke and later developed severe pneumonia also. The lady had radiological evidence of acute ischemic stroke and severe pneumonia as well as elevated D-dimer, lymphopenia, raised erythrocyte sedimentation rate, high C reactive protein (CRP) and serum ferritin. She was managed symptomatically for both pneumonia and acute stroke. Our case emphasizes that cerebrovascular disease in COVID-19 may simultaneously develop, increased C reactive protein, serum ferritin and D-dimer may contribute to the hypercoagulability and in the formation of acute ischemia. Elderly patients with co-morbidities like hypertension, diabetes, vascular disease, dyslipidaemia may contribute to acute stroke in addition to coronavirus disease pathology.

### Introduction

In December 2019, severe acute respiratory syndrome coronavirus 2 (SARS-CoV-2) emerged in Wuhan, China [1]. Since then, it rapidly spread throughout the world including Bangladesh. Till November 24, 2020, it generated 41,157,776 confirmed coronavirus disease cases with a total number of deaths were 1,402,042 worldwide [2]. Up to November 24, 2020, total confirmed cases were 449,760 with total number of deaths were 6,416 in Bangladesh [3]. It is transmitted by human-to-human transmission via direct contact or by aerosols [4]. Clinical presentation of the cases has been reported as mild (influenza like illness), moderate

(pneumonia), severe (severe pneumonia), critical (ARDS, Sepsis/septic shock) [5].

Corona virus disease 2019 produces multisystem involvement and complications including acute respiratory distress syndrome (29%), anaemia (15%), acute cardiac injury (12%), and secondary infection (10%) [6]. Evidence also suggests that coronavirus also produce neurologic symptoms including dizziness, headache, ataxia and seizure, anosmia and taste impairment. Ischemic stroke may develop in 0.9% to 2.3% of patients suffering from COVID-19 [7]. Focal neurological deficit may present in the early onset of the disease or in association with respiratory symptoms [8]. Poor outcomes and severe complications with

DOI: 10.21608/mid.2020.49170.1086

\* Corresponding author: Md Reaz Uddin Chowdhury

E-mail address: mail2dreaz@gmail.com

COVID-19 infection associated with presence of vascular risk factors such as hypertension, ischemic heart disease, diabetes mellitus and chronic kidney disease [9]. It has been observed that SARS-CoV-2 virus can cause a cytokine storm through ACE-2 receptor binding leading to a hypercoagulable state and increased incidence of vascular thrombosis in patients suffering from COVID-19 [10].

The aim to report this case, to describe the clinical characteristics of the patient during presentation, treatment response of the case, choice of anti-thrombotic and to provide possible evidence that SARS-CoV-2 induced inflammation and hypercoagulability contributed to an increased risk for cerebral arterial thrombosis resulting acute ischemic stroke in our patient. Another aim is to familiarize our fellow colleague to share the experience of unusual presentation of COVID-19 with multiple co-morbidities presenting with cerebrovascular complications.

### Case presentation

A 70-year-old woman presented to the Medinova Specialized Hospital, Feni Bangladesh on July, 16, 2020 with the complains of sudden onset of left sided weakness for 4 hours, inability to speak and deviation of the face for same duration. On query her attendants also told that she was suffering from high grade intermittent fever for last 7 days, for that she had to take paracetamol three to four times daily and dry cough for 5 days without any expectoration of sputum or shortness of breath. She had no history of haemoptysis, loss of consciousness, headache, dizziness, chest pain, diarrhea or arthralgia or any unusual symptoms. Exploration of past medical history included hypertension for 10 years, diabetes mellitus for 8 years initially controlled on dieting and oral hypoglycemic agents later on subcutaneous insulin for last 4 years. She also suffered from ischemic heart disease and was taking nitroglycerin 2.6mg, trimetazidine 35mg, bisoprolol 5mg, aspirin-clopidogrel 150mg combination and a lipid lowering drug atorvastatin 20mg in the last 5 years. She reported no cerebrovascular or peripheral vascular disease.

On admission, physical examination revealed a temperature of 102 F, agitated, moderate anemia, blood pressure of 170/110 mm of Hg, pulse of 108/min with normal rhythm and volume, respiratory rate was 20 breath/min and oxygen saturation was 86% on room air put on supplemental oxygen through a simple face mask though the

patient have no acute dyspnea, Glasgow coma scale (GCS) was 9/15. Neurological examinations of the patient revealed left sided weakness of the limbs and the limb muscle strength was (MRC grading) was 3. The right leg and arm were unaffected, speech was not fluent with tongue and facial deviation. National institutes of Health Stroke Scale (NIHSS) score was 16. There was also incontinence of urine requiring an immediate catheterization. There was no leg edema, cardiac apex in normal position, first and second heart sounds were normal without any added sound, there were no carotid bruits, xanthelasma or xanthoma anywhere in the body. Lungs auscultation showed few scattered coarse crackles over the both lung fields. Real time polymerase chain reaction (RT-PCR) from nasopharyngeal swab sample was found positive on the following day.

Computed tomography of Brain (Ct scan of Brain) without contrast was performed immediately which revealed large hypodense areas noted at right temporo-parietal region, diffuse hypodensities at subcortical and periventricular white matter of both cerebral hemispheres suggesting large acute infarct at right temporo-parietal region with age related generalized cerebral and cerebella atrophy with white matter ischemic change and features of normal pressure hydrocephalus (**Figure 1A & B**). Following RT-PCR positive result, high resolution computed tomography of chest (HR CT of Chest) also performed which revealed multifocal ground glass opacity areas intermixed with irregular increased attenuated areas, fibrotic bands and early sub segmental consolidations are seen at multiple segments of both lungs predominantly distributed at peripheral, peri bronchoalveolar and subpleural regions. The ground glass density involved approximately 30% of lung volume (**Figures 2 & 3**).

Other significant laboratory findings included (**Table 1**); hemoglobin was 7.9gm/dl, packed cell volume (PCV) was 26.0%, erythrocyte sedimentation rate (ESR) was 55 mm in 1<sup>st</sup> hour, total white blood cell count (WBC) was 23,400/cmm with 88% neutrophils and 8% lymphocytes in differential counts, platelet count was 340,000/cmm, serum creatinine was 1.2 mg/dl with estimated GFR was 87 ml/min/1.73m<sup>2</sup>, C reactive protein was 87mg/L, alanine aminotransferase was 14 U/L, serum lactate dehydrogenase was 565 U/L, serum ferritin was 1000ng/ml, D-dimer was 2.69 mg/l, serum urea was 34 mg/dl, serum calcium was 6.4 mg/dl, troponin I was <0.01 ng/ml, N terminal Pro-

brain natriuretic peptide (NT-Pro-BNP) was 410 pg/ml, serum sodium was 136 mmol/l, potassium was 3.6mmol/l, random blood sugar was found 18.0 mmol/l on admission. Trans thoracic echocardiography showed concentric hypertrophy with normal left ventricular function (Ejection fraction 64%) and inferior wall motion abnormality. She was started on low molecular weight heparin, enoxaparin 60mg subcutaneous 12 hourly, aspirin 75mg, oral favipiravir 1600mg loading dose followed by maintenance dose of 600 mg twice daily for 10 days according to national guideline of Bangladesh, Intravenous antibiotic ceftriaxone 2gm twice daily with oral clarithromycin twice daily for possible bacterial co-infection, continuous infusion of short acting insulin was started and corticosteroid, dexamethasone for 5 days along with her regular antihypertensive losartan potassium 50mg/hydrochlorothiazide 12.5mg, clopidogrel 75mg, nitroglycerine 2.6mg, trimetazidine 35mg, bisoprolol 5mg and atorvastatin 20 mg daily. She was put on nasogastric tube for maintaining adequate feeding. She was admitted in isolation unit and started on supplemental oxygen therapy via simple face mask at 5L/min. She positively responded to treatment meanwhile after 5 days sudden desaturation occurred requiring supplemental oxygen 25L/min through High flow

**Table 1.** Clinical laboratory finding from hospital (Day 1-Day 17) :( July,16, 2020-August,04,2020).

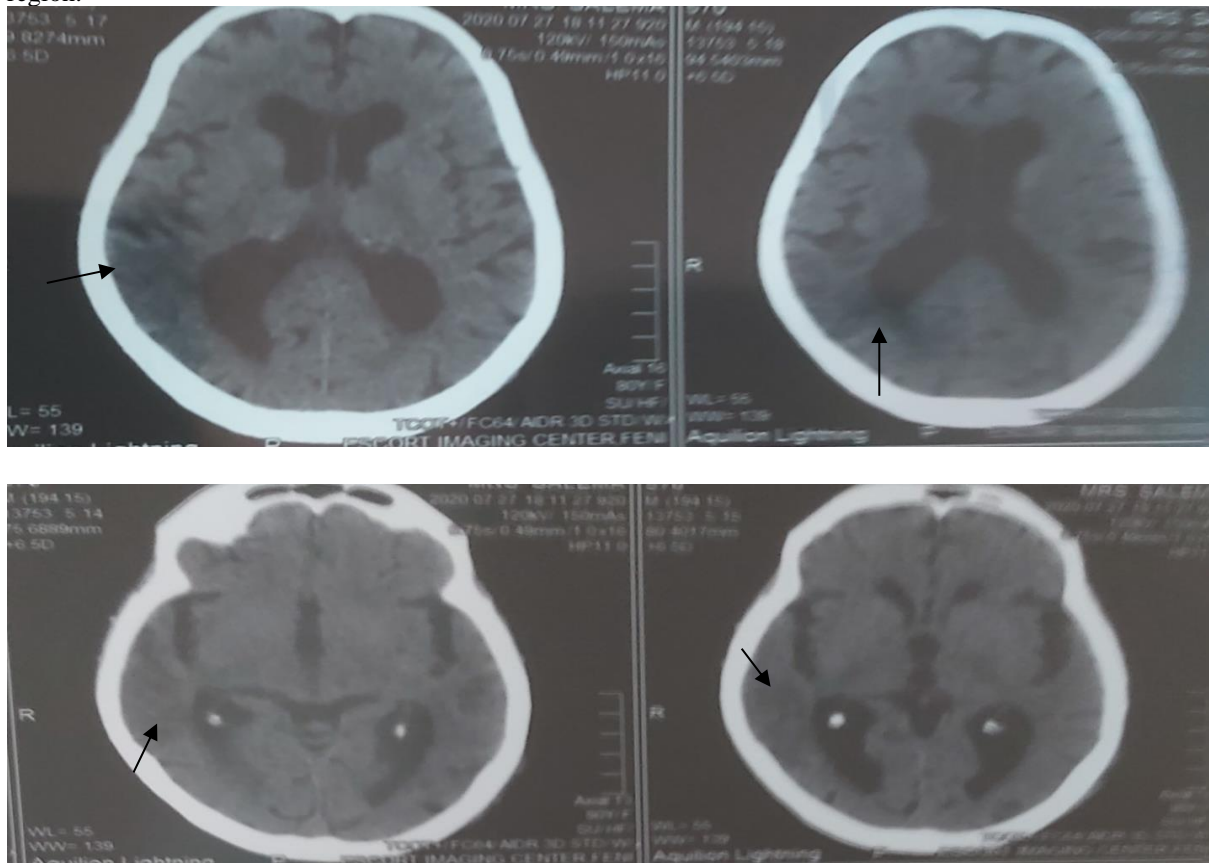
Measurement (Reference range)	Day 1	Day 8	Day 18
Hemoglobin (Female 11-16gm/dl)	7.9gm/dl	9.2mg/dl	9.1gm/dl
Erythrocyte Sedimentation rate (ESR) (0-15 mm in 1 <sup>st</sup> hour)	55mm in 1 <sup>st</sup> hour	87mm in 1 <sup>st</sup> hour	49mm in 1 <sup>st</sup> hour
Total White blood cell count (WBC)(4000-11,000/cmm)	23,400/cmm	18,700/cmm	15,000/cmm
Neutrophils (Differentials)(40-75%)	88%	79%	71%
Lymphocytes (Differential)	08%	14%	11%
Haematocrit (37-47%)	26%	28.8%	28%
Platelet count (150,000-400,00/cmm)	340,000/cmm	290,000/cmm	272,000/cmm
Sodium(135-145nmol/L)	136.0nmol/L	138nmol/L	134nmol/L
Potassium (3.5-5.0nmol/L)	3.60nmol/L	4.5nmol/L	4.9nmol/L
Chloride(98-107nmol/L)	106nmol/L	109nmol/L)	102nmol/L
Serum calcium (8.1-10.4mg/dl)	6.4mg/dl		
Serum creatinine (0.5-1.2mg/dl)	1.2mg/dl	1.0mg/dl	1.2mg/dl
Blood urea nitrogen (BUN)(6.0-21mg/dl)	12.7mg/dl		
Total Bilirubin (0.2-1.2mg/dl)	1.2mg/dl	1.3mg/dl	
Blood Urea(10-50mg/dl)	34mg/dl		41mg/dl
Prothrombin time (Control 13.sec)	17.0 sec	14.0sec	18.0 sec
Alanine aminotransferase (Female up to 32 U/L)	14U/L		32U/L
C reactive protein (less than 6mg/L)	87mg/l	43.6mg/l	42.8mg/ml
D-dimer (<0.5 mg/ml)	2.69 mg/l	2.1mg/l	0.9mg/l
Activated plasma thromboplastin time (APTT)(25-35)		Control:32 Patient:21	Control:32 Patient:25

nasal canola for five days and starting antiviral remdesivir for 5 days according to national guideline without any adverse events. After that she was maintaining saturation above 92% with a non-ther mask with 10-12 L/min oxygen. Alternate day electrocardiogram showed no new ischemic change or arrhythmia. She was given 2 units of packed cell blood transfusion during her hospital stay. She remained on regular physiotherapy, speech therapy and chest therapy during her hospital stay.

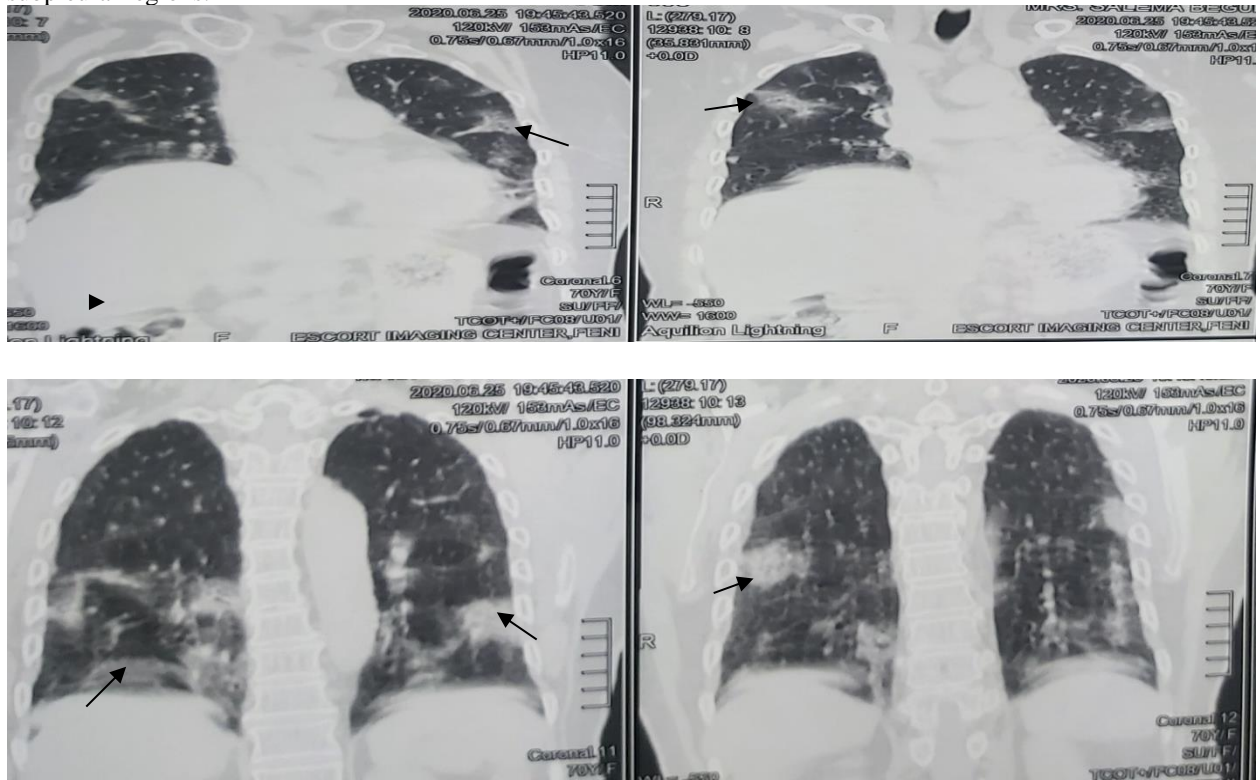
After 17 days stay in the hospital, her clinical and laboratory parameters improved along with slight radiological (X ray chest) improvement (**Figure 4**). The patient-maintained saturation above 92% on room air without supplemental oxygen therapy. Her nasogastric tube was withdrawn and started oral feeding with supervision, she can walk little with help and near fluent language, but urethral catheterization could not possible to off due to urinary incontinence following failed attempt of withdrawal. On August 4,2020, she was discharged from hospital with a hemodynamic stable condition though follow up RT-PCR for coronavirus could not done due to changing discharge criteria in the national guideline of Bangladesh. She was advised for 14 days home isolation and a follow up visit after 14 days in the outpatient department.

Troponin I(<0.1ng/ml)	<0.01ng/ml		0.06ng/ml
Serum Ferritin (Adult Female 15-120ng/ml)	1000ng/ml	1122ng/ml	734ng/ml
N terminal Pro BNP (<300pg/ml HF unlikely)	410pg/ml		477pg/ml
Lactate dehydrogenase(200-400U/L)	565U/L		470U/L
Serum Procalcitonin (<0.1ng/ml)	<0.05ng/ml		
Thyroid stimulating hormone (TSH)(0.3-5.05µIU/ml)	4.50µIU/ml		
Malarial Parasite	Not found		
NS1 antigen and ICT for Dengue	Negative		
Electrocardiogram (ECG)	Left ventricular hypertrophy with inferior wall motion abnormality		
Sero immunological Test for Salmonella, Brucella and Rickettsia	Not significant		
Blood culture	No growth		
Serum Cholesterol(<200mg/dl)	280mg/dl		
Serum Triglycerides(<150mg/dl)	232mg/dl		
High density lipoprotein (HDL)(>80mg/dl)	40mg/dl		
Low density lipoprotein (LDL)(100-130mg/dl)	152mg/dl		

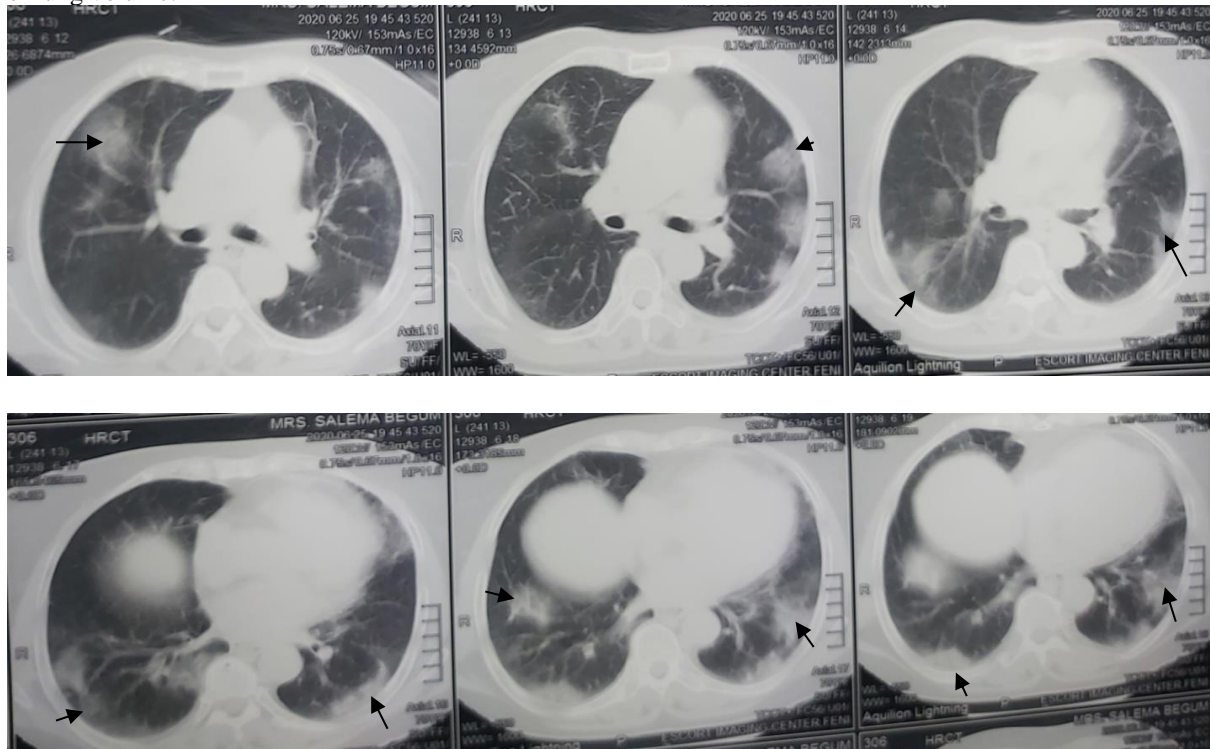
**Figure 1 (A and B).** Computed tomography of brain without contrast was performed immediately which revealed large hypodense areas noted at right temporoparietal region, diffuse hypodensities at subcortical and periventricular white matter of both cerebral hemispheres suggesting large acute infarct at right temporo-parietal region.



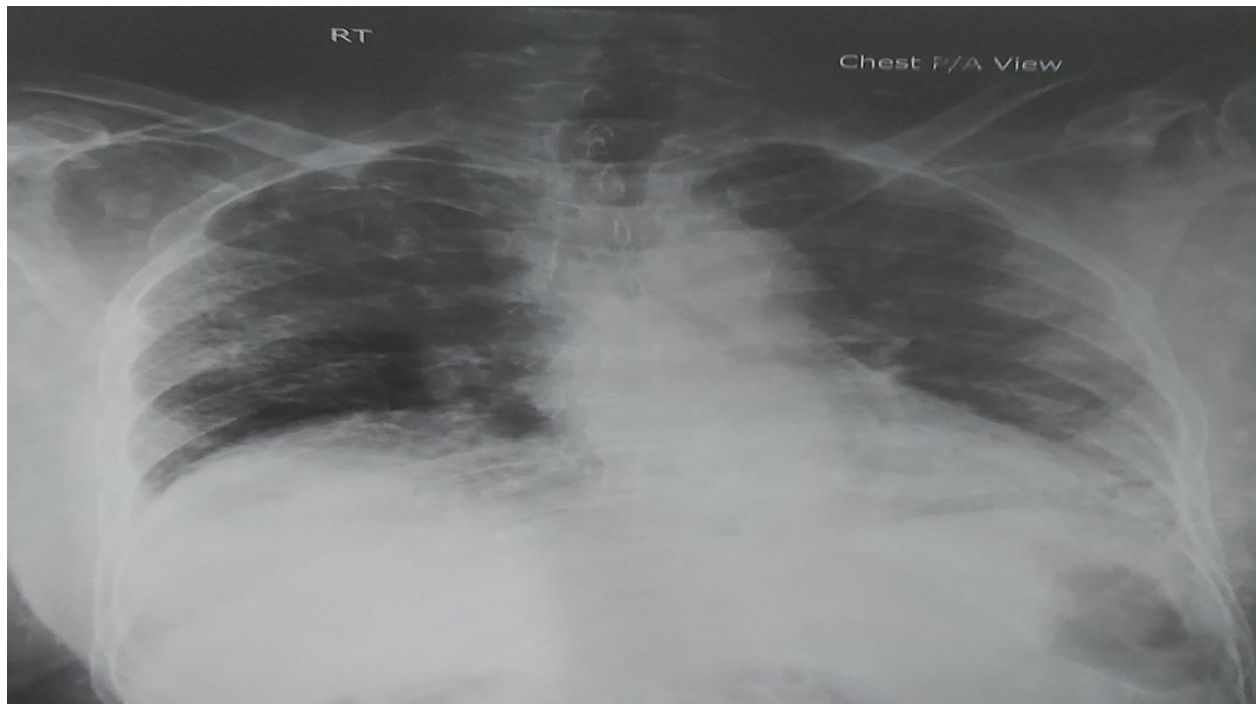
**Figure 2 (A and B).** HR CT of chest (Coronal views) showing multifocal ground glass density (black arrows) areas intermixed with irregular increased attenuated areas, fibrotic bands and early sub segmental consolidations are seen at multiple segments of both lungs predominantly distributed at peripheral, peri bronchoalveolar and subpleural regions.



**Figure 3(A and B).** HR CT of chest (Axonal views) showing (black arrows) multifocal ground glass density and early sub segmental consolidations are seen at multiple segments of both lungs predominantly distributed at peripheral, peri bronchoalveolar and subpleural regions. The ground glass density involved approximately 30% of lung volume.



**Figure 4.** Follow Up X-ray chest showing patchy opacities are noted in both hemi thorax. (Radiological improvement lagged behind the clinical improvement).



#### Discussion

SARS-CoV-2 pandemic crisis worldwide impact a major health problem with significant morbidity and mortality to the patients. It is also a major challenge to the physicians. The SARS-CoV-2 infection more likely to affect the elderly males with co-morbidities [11]. Though our patient was an elderly female with multiple co-morbidities. Our patient was a 70 year old female with diabetes, hypertension and ischemic heart disease developing sudden onset of left sided weakness, facial deviation and slurring of speech confirming acute cerebrovascular event established the fact that elderly patient always have higher risk factors associated with ischemic stroke or embolization vascular events. Our patient was presented with acute ischemic stroke with left sided hemi paresis and high-resolution computed tomography later found typical features of COVID-19 pneumonia. As the patient first presented with facial deviation and left sided weakness followed by respiratory symptoms, it has been hypothesized that coronavirus caused profound secretion of inflammatory cytokines which induced hypoxia and hypercoagulability resulting acute ischemic stroke contributes by other co-morbidities-hypertension, diabetes and dyslipidaemia. Hypoxia induce cell damage and a cascade to induce more inflammatory response including inflammatory cell infiltration and more cytokine release, leading to further cell injury [12]. One study also showed that inflammation contributes to atherosclerosis and affect plaque stability [13]. So, it plays an important

role for the development of cerebrovascular as well as cardiovascular diseases.

From the above study findings we can presume that coronavirus infection is one of the pathogenesis of ischemic stroke as in a previous study also showed that virus can induce vasculopathy, this has been described in varicella zoster virus, cytomegalovirus and human immunodeficiency virus [14]. Another study hypothesized that pro-coagulant and inflammatory cascade activated in infection due to increase in interleukin 1, decrease in the anticoagulant protein C [15]. So immediate prophylactic anticoagulation may reduce the risk of ischemic stroke in COVID-19 patients [16]. In our case, she started immediately with anticoagulation and showed positive response. As still there is no evidence-based treatment of COVID-19, preliminary data suggest that remdesivir may improve outcome [17]. So, we used it carefully to the patient along with other drugs.

Another study showed that majority of the patients had elevated inflammatory markers such as D-dimer, serum ferritin, C reactive protein and IL-6 which also similar to investigation findings in our patient [18]. Though elevated D-dimer are suggestive of hypercoagulability, it do not establish causality between cerebrovascular disease and COVID-19 but a consensus study also suggest that D-dimer levels in the early stage COVID-19 pneumonia could indicate inflammatory response, it can also represent acute thrombosis and monitoring D-dimer may be useful for the timely diagnosis of a

thrombotic complication [19,20]. our report also suggesting this.

### Conclusions

Our case concludes that SARS-CoV-2 infection may present with neurological deficits in addition to respiratory symptoms. Immediate diagnosis and treatment with anti-thrombotic drugs, supportive therapy, well management of the comorbidities particularly diabetes and hypertension are necessary for a good outcome. Testing for coronavirus should also keep in mind who present with neurological symptoms during this pandemic crisis. Further large-scale study is also recommended for a definite outcome and guideline for the physicians.

### Funding

This research did not receive any specific grant from funding agencies in the public, commercial or not for profit sectors.

### Declaration of competing interest

The authors declare that they have no known competing financial interest or personal relationships that could have appeared to influence the work reported in this paper.

### Statement of ethics

Informed consent was obtained from the patient for publication of this case report.

### Acknowledgement

To all the staffs of Medinova Specialized Hospital specially Dr Moksedul Maola, Managing director Mr Humayun, Abdul Hafiz, Mizanur Rahman, Abdul Quddus Sumon for their tremendous support in the different stage of treatment of the patient

### References

- 1- **Huang C, Wang Y, Li X, Ren L, Zhao J, Hu Y, et al.** Clinical features of patients infected with 2019 novel coronavirus in Wuhan, China. *The lancet* 2020;395(10223):497-506.
- 2- **Worldometers.** COVID-19 coronavirus pandemic. Available at <https://www.worldometers.info/2020> August 04. Accessed November 24, 2020.
- 3- **WHO.** Novel Corona Virus (COVID-19) Situation Reports. Available at [https://www.who.int/docs/default-source/searo/bangladesh/covid-19-who-bangladesh-situation-reports/who-ban-covid-19-sitrep-10.pdf?sfvrsn=c0aac0b8\\_4](https://www.who.int/docs/default-source/searo/bangladesh/covid-19-who-bangladesh-situation-reports/who-ban-covid-19-sitrep-10.pdf?sfvrsn=c0aac0b8_4). Accessed November 12, 2020.
- 4- **Li Q, Guan X, Wu P, Wang X, Zhou L, Tong Y, et al.** Early transmission dynamics in Wuhan, China, of novel coronavirus-infected pneumonia. *New England Journal of Medicine* 2020; 382:1199-1207.
- 5- **Directorate General of Health Services.** National Guideline on Clinical Management of Coronavirus Disease 2019(COVID-19). Available at <https://www.dghs.gov.bd>. Accessed November 14, 2020.
- 6- **Lai CC, Shih TP, Ko WC, Tang HJ, Hsueh PR.** Severe acute respiratory syndrome coronavirus 2 (SARS-CoV-2) and corona virus disease-2019 (COVID-19): the epidemic and the challenges. *International journal of antimicrobial agents* 2020:105924.
- 7- **Mao L, Jin H, Wang M, Hu Y, Chen S, He Q, et al.** Neurologic Manifestations of Hospitalized Patients with Coronavirus Disease 2019 in Wuhan, China. *JAMA Neurol* 2020;77(6):683-690.
- 8- **Yaghi S, Ishida K, Torres J, Mac Grory B, Raz E, Humbert K, et al.** SARS2-CoV-2 and stroke in a New York healthcare system. *Stroke* 2020; 51(7):2002-11.
- 9- **Chowdhury MR, Akter KS, Bhuiyan SI, Khabir MK, Das BC, Kabir MA.** A Physician Suffering from COVID-19 with Multiple Co-Morbidities Have Delayed Viral Clearance: A Case Report from Bangladesh. *Advances in Infectious Diseases* 2020 29;10(03):94.
- 10- **Connors JM, Levy JH.** COVID-19 and its implications for thrombosis and anticoagulation. *Blood. The Journal of the American Society of Hematology* 2020 ;135(23):2033-40.
- 11- **Chen N, Zhou M, Dong X, Qu J, Gong F, Han Y, et al.** Epidemiological and clinical

- characteristics of 99 cases of 2019 novel coronavirus pneumonia in Wuhan, China: a descriptive study. *The Lancet* 2020;395(10223):507-13.
- 12-**Li S, Hafeez A, Noorulla F, Geng X, Shao G, Ren C, et al.** Preconditioning in neuroprotection: from hypoxia to ischemia. *Progress in neurobiology* 2017; 157:79-91.
- 13-**Hartmann P, Schober A, Weber C.** Chemokines and microRNAs in atherosclerosis. *Cellular and Molecular Life Sciences* 2015;72(17):3253-66.
- 14-**Nagel MA, Mahalingam R, Cohrs RJ, Gilden D.** Virus vasculopathy and stroke: an under-recognized cause and treatment target. *Infectious Disorders-Drug Targets (Formerly Current Drug Targets-Infectious Disorders)* 2010;10(2):105-11.
- 15-**Grau AJ, Buggle F, Becher H, Zimmermann E, Spiel M, Fent T, et al.** Recent bacterial and viral infection is a risk factor for cerebrovascular ischemia: clinical and biochemical studies. *Neurology* 1998 ;50(1):196-203.
- 16-**Beyrouiti R, Adams ME, Benjamin L, Cohen H, Farmer SF, Goh YY, et al.** Characteristics of ischaemic stroke associated with COVID-19. *Journal of Neurology, Neurosurgery & Psychiatry* 2020; 91(8):889-91.
- 17-**Grein J, Ohmagari N, Shin D, Diaz G, Asperges E, Castagna A, et al.** Compassionate use of remdesivir for patients with severe Covid-19. *New England Journal of Medicine* 2020;382(24):2327-36.
- 18-**Reddy ST, Garg T, Shah C, Nascimento FA, Imran R, Kan P, et al.** Cerebrovascular Disease in Patients with COVID-19: A Review of the Literature and Case Series. *Case Reports in Neurology* 2020;12(2):199-209.
- 19-**Zhai Z, Li C, Chen Y, Gerotziafas G, Zhang Z, Wan J.** Prevention Treatment of VTE Associated with COVID-19 Infection Consensus Statement Group. 2019. *ThrombHaemost* 2020; 120(06): 937-948.
- 20-**Chowdhury MR, Akter KS, Bhuiyan SI, Das BC, Moula MM, Khan FA, et al.** COVID-19 Complicated with Arterial Thrombosis Resulting Acute Limb Ischemia: A Case Report from Bangladesh. *Bangladesh Journal of Infectious Diseases* 2020: S50-6.