

Case report

Cerebral venous sinus thrombosis (CVST), an unusual presentation of COVID-19: A case report from Bangladesh

Sohel Rahman ^{1*}, Md Reaz Uddin Chowdhury ², Arifa Akram ³, Sahedul Islam Bhuiyan ⁴

1- Institute of Epidemiology Disease Control and Research (IEDCR), Bangladesh.

2- Abdul Malek Ukil Medical college, Noakhali, Bangladesh.

3- National Institute of Laboratory Medicine and Referral Center, Dhaka, Bangladesh.

4- Brahmanbaria Medical College, Bangladesh.

CASE REPORT INFO

Case Report history:

Received 14 July 2020

Accepted 15 August 2020

Keywords:

Venous thrombotic events

Cerebral venous sinus thrombosis

COVID-19

Case report

Bangladesh

ABSTRACT

Newly recognized pandemic infectious disease COVID-19 (Corona-virus disease) is caused by severe acute respiratory syndrome coronavirus 2 (SARS-CoV-2). This viral infection causes hypercoagulability and inflammation leading to increased incidence of both arterial and venous thrombotic events (VTEs). Therefore, patients infected with this novel virus seem to be at higher risk of thrombotic events (TEs) resulting in thromboembolic diseases, especially stroke and pulmonary embolism, or even cerebral venous sinus thrombosis (CVST). We report a case of 42-year-old female, presented with features of venous thrombotic events (extensive dural venous sinus thrombosis) and was subsequently found to have COVID-19 positive by reverse transcriptase-polymerase chain reaction (RT-PCR) test. The case report indicates CVST might be an unusual manifestation of COVID-19. Cerebral venous sinus thrombosis even presents as an initial symptom of COVID-19 without significant respiratory symptoms. Early diagnosis and treatment with thrombolytic agent in case of SARS-CoV-2 infection result in reduced morbidity and mortality. We recommend further studies to establish SARS-CoV-2 virus (the COVID-19 disease) as a known risk factor for CVST.

Introduction

Coronavirus disease (COVID-19) is a highly contagious disease caused by severe acute respiratory syndrome coronavirus 2 (SARS-CoV-2) and appears to be associated with increased thrombotic event like, deep vein thrombosis (DVT), pulmonary embolism (PE), cerebral venous thrombosis (CVT), and stroke [1–3]. Several studies [4–7] has explained the pathophysiology of venous thrombotic events (VTEs) in SARS-CoV-2 infection resulting from hypercoagulability and inflammation. However, few studies have described CVT as an initial presenting symptom of COVID-19 [2].

Cerebral venous thrombosis, an unusual rare causes of stroke, frequently occurs in female gender and young age group [8–11]. The features of CVT ranges from non-specific neurological symptoms and signs [12] including headache, vomiting, seizures, to focal neurological deficits, [11] such as motor weakness (present in up to 40% of patients), visual field loss and sensory symptoms. However, infection with SARS-CoV-2 reported to be associated with neurological manifestations, (e.g. febrile seizures, convulsions, changes in the mental status and encephalitis) [1,10,13,14]. Neurologic sequelae such as anosmia, headache, dizziness and altered

sensorium may occur due to direct viral infection or as secondary complications of SARS-CoV-2. Moreover, neurotropic and neuro-invasive capabilities of coronaviruses have been described in humans [2,11,14,15]. We present a unique case of a 42-year-old COVID positive female with features of extensive dural venous sinus thrombosis. This study was approved by the local research ethics committee. Written informed consent was obtained from the patient.

Case study

On 15th May 2020, a 42-years-old obese woman (BMI 29) with no significant past medical history or comorbidities presented with the complains of gradual onset of severe headache for 3 days and gradual onset of left sided weakness for same duration. She was referred to a nearby tertiary Medical College Hospital by an internal medicine specialist on that day, with the suspicion of cerebrovascular disease (subarachnoid haemorrhage).

On admission, she was afebrile, had a normal sinus rate and rhythm of heart, no respiratory difficulties, with no altered vision or seizure. Her history explored having no comorbidities like hypertension, diabetes mellitus, any prothrombotic condition, any history of cardiac or cerebral disease or any drug history related to the disease (oral contraceptives) or any relevant family history. On examination, her vital signs were blood pressure (BP) 130/80 mm of Hg, pulse 68/min regular with normal volume, body temperature was 99°F, respiratory rate was 16/min but the patient was looking ill with little agitating behaviour with other normal parameters in general examinations.

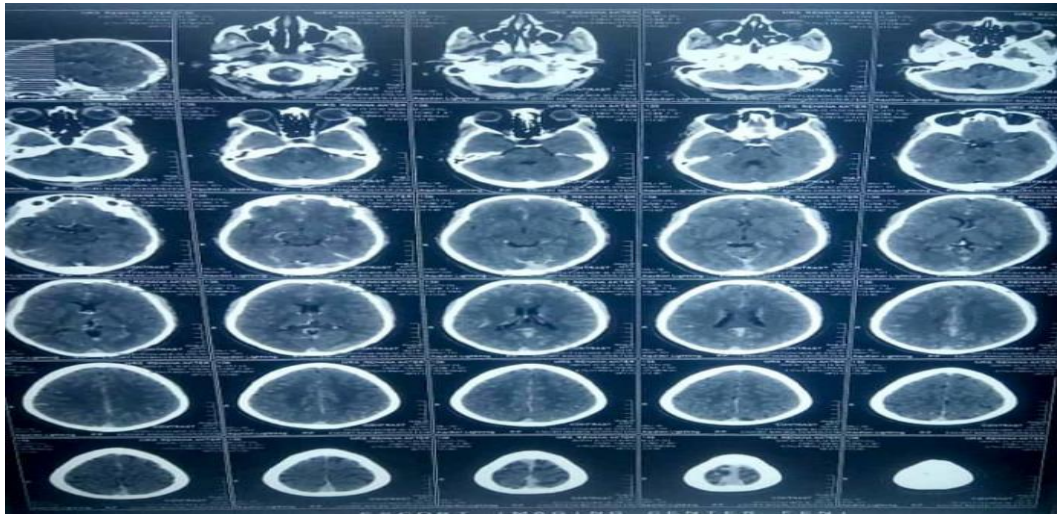
Neurological evaluation revealed left sided weakness as evidenced by decreased muscle power on the left side (both upper and lower limb -3/5 MRC-grade 3), sensory intact, planter extensor in the left side and involvement of the bladder requiring urethral catheterization. Moreover, no cerebellar sign was found but fundoscopic examination showed bilateral early papilloedema. Meanwhile, her oxygen saturation was fluctuating from admission to onward following days, from 89% to 96% on room air, requiring supplemental oxygen by simple face mask at a rate of 4 to 6 l/min. However, she had history of taking paracetamol 500 mg QDS and azithromycin 500 mg OD for five days prior to hospitalization due to sore throat which were improved within this time.

She underwent emergency head computed tomography (CT) with contrast (on 16th May) to diagnose the underlying pathology, extensive hyper densities at dural venous sinuses were found, more marked at straight and posterior part of the superior sagittal sinuses associated with dilatation of venous sinuses (**Figure1**). Prominent superficial cortical vein was also noted at both cerebral hemispheres. After intravenous contrast, filling defect were noted at dural venous sinuses (enclosed photograph).

On the following day, thrombophilia screening test and other relevant investigations were done to find out the underlying causes of thrombosis. Laboratory findings are reported in **table (1)**.

Meanwhile, reverse transcriptase-polymerase chain reaction (RT-PCR) was done on 16th May due to suspicion of COVID-19 and tested positive on 17th May 2020. However, her treatment was on going with enoxaparin 60mg s/c 12 hourly, paracetamol 1 gm IV 08 hourly, phenobarbitone IV 12hourly. After the report of RT-PCR she was shifted to an isolation unit of a dedicated COVID-19 hospital and treated according to National Guidelines on Clinical Management of Coronavirus Disease 2019. Treatment was started with oral favipiravir loading dose (1600 mg day 1) followed by maintenance dose (600mg BD Day 2 - Day 10). Her condition improved from day four and headache was totally subsided on 6th day of treatment.

Furthermore, physiotherapy was started and left sided weakness gradually improved. On 25th May she was discharged from the hospital with the advice of 10 days home isolation and the prescribed treatment was oral Rivaroxaban 20mg daily for 45 days, oral anticonvulsant levetiracetam 500mg 12 hourly, paracetamol, antioxidant Vit E and Vit C and also advised for follow up sample test for COVID-19 after isolation completion. Follow up sample was not tested due to protocol change according to national guideline and complete recovery of the patient.

Figure 1. Pictures of computed tomography with contrast.**Table 1.** Laboratory findings

Variable	Result (Reference Range)
Absolute Lymphocyte count (<i>per</i> μL)	$0.6 \times 10^3/\mu\text{L}$ (<i>per</i> μL)
ESR	27 mm in 1 st hour.
Hemoglobin (g/dL)	10.8 (11.5-15.5)
Hematocrit (%)	39 % (34.5-45.0)
Mean Corpuscular Volume (MCV) (fL)	83 (80.0-100.0)
MCH pg	28.3
Platelets (<i>per</i> μL)	175,000 (150,000-400,000)
White Blood Cell Count (<i>per</i> μL)	8.21×10^9 (<i>per</i> L)
Bleeding time (BT)	2min 15 sec
Clotting time (CT)	06 min 45sec
Activated Partial Thromboplastin Time (APTT)	(Sec.) 30 (27.5-36.3)
Anti-dsDNA	2,99 IU/ml
Anti-nuclear antibody (ANA):	Negative
S TSH	7.12 $\mu\text{U/ml}$
S Creatinine	0.9 mg/dl
C - reactive protein	27 (2-7) (mg/L)
VDRL.	Non-reactive
Chest X-ray (P/A view)	Normal
ECG	Within Normal limit
RBS (mmol/l)	5.6 mmol/l
HbA1c (%)	5.5%
Prothrombin Time (PT), Plasma (Sec.)	12.7(9.8-13.1) (Sec.)
Lactate Dehydrogenase (LDH), serum (U/L)	287 (135-225) (U/L)
Ferritin, Serum (ng/mL)	88.40 (15-150) (ng/mL)
D-Dimer Assay, Quantitative	1.63 (mg/L) <0.50mg/l

Discussion

Current pandemic infectious disease COVID-19, when symptomatic, typically presents with systemic and respiratory manifestations [2,15–17]. Emerging data also suggested that this disease

can present with neurological manifestations, in fact there are few studies about neurologic complications of COVID-19 [1,10,13,14]. Angiotensin converting enzyme-2 (ACE2) is

identified as the receptor for SARS-CoV-2, which is present in nervous system and skeletal muscles, hence this virus can infect these systems as well as the respiratory tract [14]. SARS-CoV-2 can also cause overproduction of proinflammatory cytokines (tumor necrosis factor [TNF], IL-6, and IL-1 β) resulting in cytokine storm and damage to the coagulation system causing release of D-dimer and platelet abnormalities. It increases the risk of abnormal blood clotting leading to deep vein thrombosis or pulmonary embolism [1,10]. Moreover, with COVID-19, development of severe hypoxemia in some patients results in thrombus formation under hypoxic conditions [18]. However, to the best of our knowledge our patient is the first reported case of CVT associated with COVID-19 in Bangladesh.

This case illustrates a number of diagnostic challenges, in particular presentation with isolated neurological findings. Our patient was admitted with the diagnosis of suspected CVT (confirmed subsequently), presenting features were gradual onset of severe headache with left sided weakness. Further history later on revealed mild sore throat was present five days prior to hospital admission. The suspicion of COVID-19 occurred later in the hospital due to clinical presentation of the patient without any significant correlation of thrombosis related disease but recently increasing COVID-19 cases in her surroundings residence and clinical interest of the treating physician as well as some published case reports.

Cerebral venous thrombosis is a rarely documented early presentation of COVID-19 [3]. However, incidence of CVT among female sex and young age patients is much higher than male sex and other age groups. In this case report, we found a female patient of 42 years of age suddenly developed CVT that correspond to previous study findings [9,10,12]. However, hypercoagulability of SARS-CoV-2, manifests as an increase in D-dimer, lactate dehydrogenase (LDH) and prolonged coagulation times, which are also associated with more severe disease [3]. In this case, patient had normal coagulation time and little raised LDH level. However, D-dimer level, was slightly elevated suggesting a hypercoagulable state [13].

This case demonstrates presence of thrombolytic (VTE) effect, dural venous sinus thrombosis, in the cerebral venous system in absence of additional risk factors other than

obesity. Moreover, the family history of hypercoagulability, prior history of DVT, Cardiovascular disease, cancer, collagen vascular diseases and acquired causes like brain tumor, head trauma, local central nervous system infection, none of which were present in this patient. That indicates venous sinus thrombosis might occur secondary to the hyper inflammatory state during COVID-19 [2]. So, we may consider COVID-19 as an independent risk factor for CVT. Furthermore, patients may present with thromboembolic complications, (such as CVT) prior to respiratory symptoms. So, this case report also highlights the importance of identifying CVT as a presenting sign of COVID-19 patient who presented with headache, which is also similar finding as study conducted by **Hemasian and Ansari** [13].

Regarding treatment, the selection of anticoagulants for managing a patient of VTEs associated with COVID-19 is a matter of debate [19]. Both unfractionated heparin and low molecular weight heparins (LMWH) are used in acute CVST. Emerging evidence suggests that various heparins can bind to the COVID-19 spike proteins, help downregulate IL-6, and directly dampen immune activation. In our patient we started treatment with LMWH enoxaparin instead of unfractionated heparin as the patient clinical condition was stable and there were no other comorbidities.

Conclusion:

Cerebral venous sinus thrombosis is an unusual manifestation of COVID-19 and few cases reported already worldwide. Cerebral venous sinus thrombosis even presents as an initial symptom of COVID-19 without significant respiratory symptoms. Early diagnosis and treatment with thrombolytic agent could significantly reduce morbidity and mortality. We recommend further studies to establish the COVID-19 disease as a known risk factor for CVST.

Financial disclosure: None.

Conflict of interest: None.

References

- 1-Gill I, Chan S, Fitzpatrick D. COVID-19 Associated Pulmonary and Cerebral Thromboembolic Disease. *Radiol Case Rep* 2020; 15(8): 1242-1249.

- 2-**Hughes C, Nichols T, Pike M, Subbe C, Elghenzai S.** Cerebral Venous Sinus Thrombosis as a Presentation of COVID-19. *European Journal of Case Reports in Internal Medicine* 2020; 7(5): 001691.
- 3-**Klein DE, Libman R, Kirsch C, Arora R.** Cerebral Venous Thrombosis: Atypical Presentation of COVID-19 in the Young. *J Stroke Cerebrovasc Dis* 2020; 29(8): 104989
- 4-**Ng JJ, Choong AM.** Thromboembolic events in patients with SARS-CoV-2. *J Vasc Surg* 2020; 72(2): 760-761.
- 5-**Tavazzi G, Civardi L, Caneva L, Mongodi S, Mojoli F.** Thrombotic events in SARS-CoV-2 patients: an urgent call for ultrasound screening. *Intensive Care Med* 2020; 46: 1121–1123.
- 6-**Colling ME, Kanthi Y.** COVID-19-associated coagulopathy: An exploration of mechanisms. *Vasc Med* 2020; 25(5):471-8.
- 7-**Giannis D, Ziogas IA, Gianni P.** Coagulation disorders in coronavirus infected patients: COVID-19, SARS-CoV-1, MERS-CoV and lessons from the past. *J Clin Virol* 2020;127: 104362.
- 8-**Piazza G.** Cerebral venous thrombosis. *Circulation* 2012; 125(13): 1704-9.
- 9-**Devasagayam S, Wyatt B, Leyden J, Kleinig T.** Cerebral Venous Sinus Thrombosis Incidence Is Higher Than Previously Thought: A Retrospective Population-Based Study. *Stroke* 2016; 47(9): 2180–2.
- 10-**Ferro JM, Canhão P, Stam J, Bousser M-G, Barinagarrementeria F, ISCVT Investigators.** Prognosis of cerebral vein and dural sinus thrombosis: results of the International Study on Cerebral Vein and Dural Sinus Thrombosis (ISCVT). *Stroke* 2004; 35(3): 664–70.
- 11-**Ferro JM, Canhão P.** Cerebral venous sinus thrombosis: update on diagnosis and management. *Curr Cardiol Rep* 2014; 16(9): 523.
- 12-**Ehtisham A, Stern BJ.** Cerebral venous thrombosis: a review. *The Neurologist* 2006; 12(1): 32–8.
- 13-**Hemasian H, Ansari B.** First case of Covid-19 presented with cerebral venous thrombosis: A rare and dreaded case. *Rev Neurol (Paris)* 2020; 176(6): 521.
- 14-**Mao L, Jin H, Wang M, Hu Y, Chen S, He Q, et al.** Neurologic Manifestations of Hospitalized Patients with Coronavirus Disease 2019 in Wuhan, China. *JAMA Neurol* 2020; 77(6): 683-90.
- 15-**Asadi-Pooya AA, Simani L.** Central nervous system manifestations of COVID-19: A systematic review. *J Neurol Sci* 2020; 413: 116832.
- 16-**Zhao D, Yao F, Wang L, Zheng L, Gao Y, Ye J, et al.** A Comparative Study on the Clinical Features of Coronavirus 2019 (COVID-19) Pneumonia with Other Pneumonias. *Clin Infect Dis* 2020; 71(15): 756–761.
- 17-**Zhou B, She J, Wang Y, Ma X.** A Case of Coronavirus Disease 2019 With Concomitant Acute Cerebral Infarction and Deep Vein Thrombosis. *Front Neurol* 2020; 11: 296.
- 18-**Wichmann D, Sperhake JP, Lütgehetmann M, Steurer S, Edler C, Heinemann A, et al.** Autopsy Findings and Venous Thromboembolism in Patients With COVID-19. *Ann Intern Med* 2020. DOI: doi.org/10.7326/M20-2003.
- 19-**Ferro JM, Coutinho JM, Dentali F, Kobayashi A, Alasheev A, Canhão P, et al.** Safety and Efficacy of Dabigatran Etexilate vs Dose-Adjusted Warfarin in Patients with

Cerebral Venous Thrombosis: A Randomized
Clinical Trial. *JAMA Neurol* 2019; 76(12):
1457-65.

Rahman S, Chowdhury MRU, Akram A, Bhuiyan SI. Cerebral venous sinus thrombosis (CVST), an unusual presentation of COVID-19: a case report from Bangladesh. *Microbes Infect Dis* 2021; 2(1): 9-14.