



Review article

Cerebral hydatidosis: Exceptional and challenging form of neurohydatidosis (Review)

Salem Bouomrani ^{1,2*}

1- Department of Internal medicine, Military Hospital of Gabes, Gabes 6000, Tunisia.

2- Sfax Faculty of Medicine, University of Sfax, Sfax 3029, Tunisia.

ARTICLE INFO

Article history:

Received 5 June 2020

Received in revised form 15 July 2020

Accepted 16 July 2020

Keywords:

Brain
Central nervous system
Hydatidosis
Hydatid cyst
Echinococcosis.

ABSTRACT

Human hydatidosis (cystic echinococcosis) is a parasitic infection, still endemic in several countries of the world, particularly in rural areas, posing a potential public health problem. The most frequent and classic localizations of human echinococcosis are the liver (75%) and the lungs (15%), but any other sites/organs may be involved by hydatid cyst. Central nervous system (CNS) involvement during this parasitosis (neurohydatidosis) is considered among the so-called “unusual”, “ectopic” or “aberrant” locations. Central nervous system hydatidosis is divided into two major nosological frameworks: brain and spinal involvement. Brain hydatidosis is exceptional with a prevalence estimated at less than 2% of all human hydatidosis, and the majority of cases are reported as sporadic observations. This localization represents a real diagnostic challenge for clinicians, even in endemic areas. It is characterized by its severity, these heavy functional repercussions and can sometimes be fatal. The purpose of this review is to familiarize hospital practitioners with this unusual location of hydatid cyst, to avoid its delayed diagnosis and improve its prognosis.

Introduction

Human hydatidosis (echinococcosis) is a parasitic infection, still endemic in several countries of the world, particularly in rural areas posing a potential public health problem [1,2].

Hydatidosis or cystic echinococcosis is a major anthrozoosis caused by the larvae of a parasite of the genus *Echinococcus* (*Echinococcus granulosus*). The parasitic cycle involves cattle, sheep and goats as the most frequent intermediate hosts, and numerous carnivores, especially dogs as the final host. Human is accidentally infested while consuming food or water contaminated by parasite eggs excreted in the definitive host's feces or through direct contact with infected dogs [1,2].

The most frequent and classic localizations of human hydatidosis are the liver and the lungs:

75% and 15% respectively [1,2]. More rarely other sites/organs may be involved by hydatid cyst. These localizations are so-called “unusual”, “ectopic” or “aberrant”, and represent less than 10% of cases [3-8]. These forms represent a real diagnostic challenge for clinicians [3-5,7,8].

Involvement of CNS during human hydatidosis (neurohydatidosis) remains exceptional and often very difficult to diagnose [9,10]. The majority of cases are reported as sporadic observations [9-13]. This location is characterized by its severity, these heavy functional repercussions and can sometimes be fatal [9,10].

Familiarization of hospital practitioners, particularly those in the first line, with this unusual location of hydatid cyst is highly recommended in order to avoid delayed diagnosis and improve the

prognosis of this parasitosis. This is the purpose of this review.

Epidemiology

Schematically, CNS hydatidosis is divided into two major nosological frameworks: brain and spinal involvement [9,10,14]. The cerebral localization is found in 70% of the cases of CNS hydatidosis and spinal involvement in 30% of the cases [14,15].

The brain remains an exceptional and unusual localization of human hydatidosis; its prevalence is estimated at 1-2% in large series [9-11,13,16]. Likewise, cerebral hydatidosis accounts for only less than 3% of all intracranial expansive processes [16,17].

Cerebral hydatidosis can be associated with other hydatid localizations, particularly vertebral and craniofacial [18,19], and sometimes integrate into a disseminated form of the disease with multiple visceral pulmonary and hepatic localizations [20,21]. More rarely, cerebral hydatidosis can be associated with a synchronous spinal localization [22]. The primitive cerebral forms of hydatid cyst are exceptional [23,24].

This localization of the disease can be seen at any age but seems to be more common in children [15,17,25,26]. This could be explained by the permeability of the arterial canal during the neonatal period allowing the parasite to pass from the periphery to the brain [27]. There is no significant difference in the distribution by sex, but a slight male predominance is found in some series [15,17,25,26,28].

Intracerebral hydatid cysts are often uniloculated; multiloculated forms are much rarer [29]. Their size is variable and giant brain hydatid cysts are also possible [30,31]. Likewise, their number is variable; these cysts are most often unique but can be multiple [19,20,23-34].

All parts of the brain can be affected by hydatidosis; the cerebral hemispheres remain the preferred location (particularly the territory of the middle cerebral artery [15,17,23-29].

The involvement of the left hemisphere is predominant, this could be explained by the birth of the left common carotid artery directly from the aortic arch [15,17,27].

Clinical manifestations

The clinical presentation of brain hydatid cyst is very polymorphic and non-specific [16]. It is not different from that of other brain tumors. It

depends on the location, size, and number of cysts [9,11-18,23-28].

Headache remains by far the most common symptom; otherwise, cerebral hydatidosis can be manifested by: focal neurological signs (motor deficits such as hemiplegia or hemiparesis), cerebellar syndrome, seizures, disturbances of consciousness, and/or signs of intracranial hypertension (headache, vomiting, and visual disturbances) [9,11-18,20,23-28]. More rarely the clinical presentation can be misleading and remains unknown for a long time: psychiatric manifestations such as memory disorders, personality disorders, change of character, agitation, and depressive syndrome [9,30].

It should be noted that this localization is characterized by a great anatomic-clinical discrepancy: hydatid cerebral cyst, even giant one, can remain without marked manifestation except for an intermittent headache, as in the observation of **Basarslan et al.** [31].

Laboratory findings

Hypereosinophilia is rarely found [15,17,23-29]. In front of any suspicion of hydatid disease hydatid serology must be requested. The most used methods are enzyme-linked immunosorbent assay (ELISA) and indirect hemagglutination for the detection of anti-echinococcus antibodies of IgG type. The sensitivity of this serology is low in the case of cerebral hydatidosis, and its negativity does not rule out the diagnosis. Serology would be rather beneficial in post-operative surveillance for the detection of recurrences [15,17,23-29].

Medical imaging

Medical imaging (computed tomography (CT) and magnetic resonance imaging (MRI)) is very useful for the positive diagnosis of this localization of human hydatidosis [35-37].

The diagnosis of cerebral hydatid cyst by the scanner is generally easy and only rarely poses a problem of differential diagnosis, since the appearance of cerebral hydatidosis is almost pathognomonic [15,17,23-28,32,35-37]. It is characterized by the absence of contrast enhancement and peri-lesional edema [15,17,35-37]. The presence of edema and contrast enhancement means cracking of the cyst and poses a problem of differential diagnosis with brain abscess or cystic tumor [15,17,23-28,35-37].

The multivesicular aspect is rarely described in the literature with a solid component corresponding to the detached membrane and surrounded by daughter vesicles (**Figure 1**). This aspect should not pose diagnostic problems even in non-endemic areas [27,38]. It is found in 20% of cases in the series [27]. Calcified forms are much rarer: <1% of cases [27,38].

On MRI, the hydatid cyst appears as a round or spherical formation, well limited, with a T1 hyposignal, a T2 hypersignal, and a very thin wall (peri-cyst) with characteristic relative T1 hypersignal and T2 hyposignal (**Figure 2**). The cancellation of the signal on fluid-attenuated inversion recovery (FLAIR) sequences and the frank hyposignal on diffusion sequence also characterize the hydatid cyst [15,17,23-28,32,35-38].

The relative hypersignal of certain cystic contents in T1- weighted sequences would be linked to the existence of hydatid sand. The absence of perilesional edema and contrast enhancement of uncomplicated cysts are even more marked on MRI [27,38,39].

Proton spectroscopy notes low levels of N-acetylaspartate (NAA) and creatine, small increase in choline, and peaks of lactate, pyruvate and acetate (**Figure 3**) [39,40]. It would also play a role in monitoring residual lesions or recurrences under medical treatment [39,40].

Figure 1. Axial cerebral CT: giant right parieto-occipital multivesicular hydatid cyst complicated with intracranial hypertension and a significant mass effect.

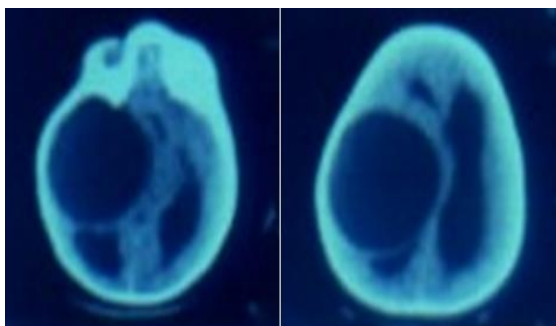


Figure 2. Cerebral MRI (T1: T1-weighted, T2: T2-weighted, Diff: diffusion-weighted, T1+G: T1-weighted with Gadolinium injection): Two cerebral hydatid cysts: unilocular right frontal and multilocular left parietal.

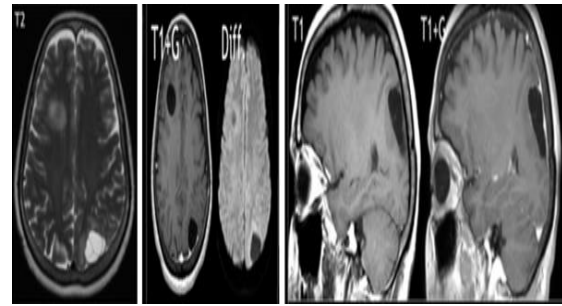
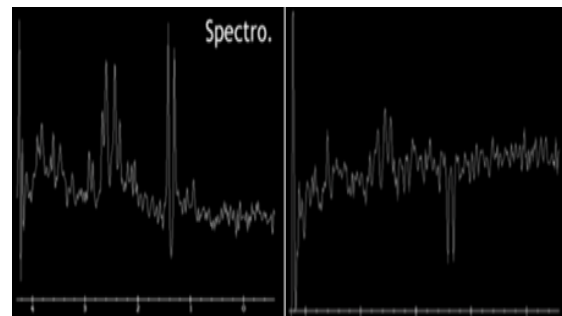


Figure 3. Cerebral proton magnetic resonance spectroscopy (Spectro) for cerebral hydatid cyst: low levels of NAA and creatine, and peaks of lactate and pyruvate.

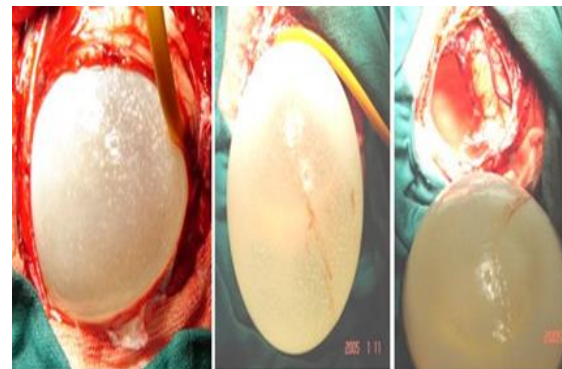


Management of cerebral hydatid cyst

The treatment of cerebral hydatid cyst is mainly surgical. However, the use of anthelmintic agents (albendazole) is recommended to sterilize the cyst, reduce the risk of anaphylaxis, reduce the parietal tension of the cyst, and reduce recurrences after the surgery [17,20,23,25- 27,32]. The use of corticosteroids can be discussed in cases of significant focal edema. In disseminated forms, multiple cysts, and in inoperable patients, drug therapy alone can be effectively prescribed [34].

The goal of surgery is to remove the cyst without rupturing it (**Figure 4**). The puncture-aspiration technique is less commonly used and is reserved for cysts with a significant risk of rupture such as cysts of the fourth ventricle, cysts of the brainstem and thalamus [17,20,23,25-27,32].

Figure 4. Surgery of cerebral hydatid cyst.



Prognosis of cerebral hydatidosis

Cerebral hydatidosis is usually a benign condition once diagnosis and management are made in time [15,17,23-29]. Local recurrence can be seen in up to 30% of cases [15]. The severe, life-threatening [41], and fatal [9] forms remain exceptional.

Brainstem compression is a possible complication of cerebral hydatidosis, particularly for giant cysts and those of the posterior fossa [39].

The rupture of the cyst spontaneously or intraoperatively represents the most frequent and most redoubtable complication and can cause anaphylactic shock or severe meningitis if the hydatid sand passes into the subarachnoid space [15].

The possible medium- and long-term complications of operated cerebral hydatidosis are post-operative seizures, subarachnoid effusion which may require the establishment of a subarachnoid-peritoneal shunt, pneumocephaly, obstructive hydrocephalus requiring ventriculo-peritoneal shunt, and transient or persistent neurological deficit [15,17,23-29].

Conclusion

The cerebral localization of human hydatidosis remains rare, little known, and often diagnosed late. Although it is most often benign, it can be the cause of severe and sometimes even fatal complications.

A better knowledge of this location by any health professional is necessary, especially those working in endemic areas for this parasitosis. Only an early diagnosis and an appropriate and rapid management are the guarantees of a good prognosis of cerebral hydatidosis.

Conflicts of interest: None

Financial disclosure: None

References

- 1-Wen H, Vuitton L, Tuxun T, Li J, Vuitton DA, Zhanget W, et al. Echinococcosis: Advances in the 21st Century. Clin Microbiol Rev 2019; 32(2): e00075-18.
- 2-Almulhim AM, John S. Echinococcus Granulosus (Hydatid Cysts, Echinococcosis). In: StatPearls. Treasure Island (FL): StatPearls Publishing; 2020.
- 3-Bouomrani S, Dabboussi S, Nefoussi M, Trabelsi S, Baïli H. Juvenile Primary Mediastinal Hydatid Cyst. EC Pulmonology and Respiratory Medicine 2018; 7: 11.
- 4-Bouomrani S, Souissi S, Regaïeg N, BenHamed M. Primary Hydatid Cyst of the Thyroid Gland Revealed by Primary Hypothyroidism. J Inf Dis Trav Med 2018; 2(3): 000121.
- 5-Bouomrani S, Souissi O, Guermazi M, Yahyaoui S, Trabelsi S. An Unexpected Etiology of Myocardial Ischemia in Young. JHC 2019; 2(4): 13-19.
- 6-Bouomrani S, Feki W. The “double wall” sign: A helpful sign for the diagnosis of orbital hydatidosis. J Clin Med Imag 2019; 2(1): 12.
- 7-Bouomrani S, Feki W. Pancreatic and gastrointestinal hydatidosis. Gastroenterol Hepatol Open Access 2019; 10(2): 108-110.
- 8-Bouomrani S, Letaïef W. Primary and Isolated Renal Hydatid Cyst in Systemic Lupus Erythematosus. Clin Res Infect Dis 2020; 5(1): 1052.
- 9-Bouomrani S, Regaïeg K, Belgacem N, Souissi O, Guermazi M, Krimi S. Misdiagnosed behavior change revealing fatal primitive intra-cerebral echinococcosis. Adv Health Behav 2019; 2(1): 62-65.
- 10-Bouomrani S, Khlass N, Ben Ayed M, Souissi O, Regaïeg N. Paraplegia Revealing Primary Extradural Spinal Hydatidosis. CPQ Neurology and Psychology 2019; 1(5): 01-06.
- 11-Siyadatpanah A, Brunetti E, Emami Zeydi A, Moghadam YD, Agudelo Higueta NI. Cerebral Cystic Echinococcosis. Case Rep Infect Dis 2020; 2020: 1754231.
- 12-Tural Kara T. A Rare Mass in the Brain in A Child: Hydatid Cyst. Turkiye Parazitolo Derg 2019; 43(2): 99-101.

- 13-**Gök H, Başkurt O.** Giant Primary Intracranial Hydatid Cyst in Child with Hemiparesis. *World Neurosurg* 2019; 129: 404-406.
- 14-**Padayachy LC, Dattatraya M.** Hydatid disease (Echinococcus) of the central nervous system. *Childs Nerv Syst* 2018; 34(10): 1967-1971.
- 15-**Limaïem F, Bellil S, Bellil K, Chelly I, Mekni A, Khaldi M, et al.** Primary hydatidosis of the central nervous system: a retrospective study of 39 Tunisian cases. *Clin Neurol Neurosurg* 2010; 112(1): 23-28.
- 16-**Kandemirli SG, Cingoz M, Olmaz B, Akdogan E, Cengiz M.** Cerebral Hydatid Cyst with Intraventricular Extension: A Case Report. *J Trop Pediatr* 2019; 65(5): 514-519.
- 17-**Ciurea AV, Fountas KN, Coman TC, Machinis TG, Kapsalaki EZ, Fezoulidis NI, et al.** Long-term surgical outcome in patients with intracranial hydatid cyst. *Acta Neurochir (Wien)* 2006; 148(4): 421-6.
- 18-**Ogul H, Kantarci M.** Primary Alveolar Echinococcosis Presenting with Simultaneous Cerebral and Craniofacial Involvement. *J Craniofac Surg* 2018; 29(7): e637-e639.
- 19-**Tzili N, Ahbeddou S, Ahmimech J, Abboud H, Boutarbouch M, El Hassan A, et al.** Swollen eyelid reveals multiple intracranial hydatid cysts associated with a palpebral cyst. *J Fr Ophtalmol* 2016; 39(2): 210-212.
- 20-**Chen S, Li N, Yang F, Wu J, Hu Y, Yu S, et al.** Medical treatment of an unusual cerebral hydatid disease. *BMC Infect Dis* 2018; 18(1): 12.
- 21-**Ijaz L, Mirza B, Nadeem MM, Saleem M.** Simultaneous giant hydatid cysts of brain and liver. *J Coll Physicians Surg Pak* 2015; 25(Suppl 1): S53-S55.
- 22-**Cheng J, Meng J, He W, Hui X.** Alveolar echinococcosis presenting with simultaneous cerebral and spinal involvement. *Neurology* 2017; 88(22): 2153-2154.
- 23-**Luo K, Luo DH, Zhang TR, Wen H.** Primary intracranial and spinal hydatidosis: a retrospective study of 21 cases. *Pathog Glob Health* 2013; 107(2): 47-51.
- 24-**Brízuela M, Sarkis C, González R, Paulin P, Lubieniecki F, Berberian G.** Cerebral hydatid disease: report of six pediatric cases. *Rev Chilena Infectol* 2017; 34(3): 270-275.
- 25-**Turgut M.** Hydatidosis of central nervous system and its coverings in the pediatric and adolescent age groups in Turkey during the last century: a critical review of 137 cases. *Childs Nerv Syst* 2002; 18(12): 670-683.
- 26-**Nourbakhsh A, Vannemreddy P, Minagar A, Toledo EG, Palacios E, Nanda A.** Hydatid disease of the central nervous system: a review of literature with an emphasis on Latin American countries. *Neurol Res* 2010; 32(3): 245-251.
- 27-**Lunardi P, Missori P, Di Lorenzo N, Fortuna A.** Cerebral Hydatidosis in Childhood: A Retrospective Survey with Emphasis on Long-term Follow-up. *Neurosurgery* 1991; 29(4): 515-8.
- 28-**Altinörs N, Bavbek M, Caner HH, Erdogan B.** Central nervous system hydatidosis in Turkey: a cooperative study and literature survey analysis of 458 cases. *J Neurosurg* 2000; 93(1): 1-8.
- 29-**Rumana M, Mahadevan A, Nayil Khurshid M, Kovoov JME, Yasha TC, Santosh V, et al.** Cestode parasitic infestation: intracranial and spinal hydatid disease--a clinicopathological study of 29 cases from South India. *Clin Neuropathol* 2006; 25(2): 98-104.
- 30-**Polat G, Ogul H, Sengul G.** Hydatidosis Following Giant Cerebral Hydatid Cyst

- Operation. *World Neurosurg* 2018; 118: 14-15.
- 31-**Basarslan SK, Gocmez C, Kamasak K, Ceviz A.** The Gigant primary cerebral hydatid cyst with no marked manifestation: a case report and review of literature. *Eur Rev Med Pharmacol Sci* 2015; 19(8): 1327-1329.
- 32-**Gupta A, Singh S, Madan D.** Multiple Intracranial Cystic Brain Lesions: A Diagnostic Dilemma. *Pediatr Neurol* 2019; 93: 56-58.
- 33-**Tanki H, Singh H, Raswan US, Bhat AR, Kirmani AR, Ramzan AU.** Pediatric Intracranial Hydatid Cyst: A Case Series with Literature Review. *Pediatr Neurosurg* 2018; 53(5): 299-304.
- 34-**Svrckova P, Nabarro L, Chiodini PL, Jäger HR.** Disseminated cerebral hydatid disease (multiple intracranial echinococcosis). *Pract Neurol* 2019; 19(2): 156-163.
- 35-**Abbassioun K, Amirjamshidi A, Sabouri Deylamie M.** Hydatid Disease of the Central Nervous System Imaging Characteristics and General Features. *Iran J Radiol* 2003; 2: 125-31.
- 36-**Abdel Razek AAK, Watcharakorn A, Castillo M.** Parasitic Diseases of the Central Nervous System. *Neuroimaging Clin N Am* 2011; 21(4): 815-41.
- 37-**Yadav VK, Sudhakar SV, Panwar J.** Pathognomonic MRI and MR spectroscopy findings in cerebral hydatid cyst. *Acta Neurol Belg* 2016; 116(3): 353-355.
- 38-**Tlili-Graïess K, El-Ouni F, Gharbi-Jemni H, Arifa N, Moulahi H, Mrad-Dali K, et al.** Cerebral hydatid disease: imaging features. *J Neuroradiol J Neuroradiol* 2006; 33(5): 304-18.
- 39-**Basraoui D, El Idrissi I, Jalal H, Hiroual M, Essadki O, Ousehal A, et al.** Intracranial Hydatid Cysts in Children: A Report of 9 Cases. *J Radiol* 2010; 91: 293–6.
- 40-**Sahin-Akyar G.** Computed tomography and magnetic resonance imaging findings in cerebral hydatid disease. *Radiography* 2002; 8: 251-8.
- 41-**Karakoç ZC, Kasimcan MO, Pipia AP, Tore G, Alberti A, Varcasiaet A, et al.** A life-threatening brainstem compression by cerebral *Echinococcus granulosus*. *Infez Med* 2016; 24(1): 62-66.